

Prognostic Significance and Therapeutic Implications of CD34, an Angiogenic Marker, in Oral Squamous Cell Carcinoma: A Narrative Review

NIVA MAHAPATRA¹, S NITHYA², DIVYA UPPALA³, SOUNDARYA SRINIVASAN⁴, DAFFNEY MANO DOSS⁵

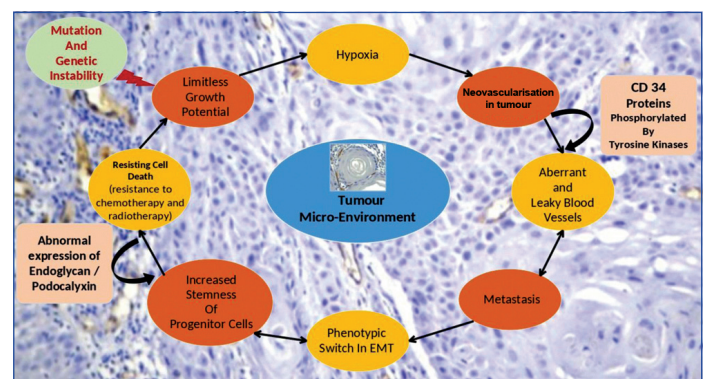
ABSTRACT

Head and neck cancer is the 7th most common malignancy worldwide. Few decades earlier, there has been an enormous rise in genetic events as the source in the development of Oral Squamous Cell Carcinoma (OSCC) and metastasis to various organs. The seeding of neoplastic cells occurs via blood vessels (haematogenous spread), lymphatics (lymphogenous spread), or invasion into body cavities (transcoelomic spread). Neoangiogenesis results in haematogenous spread from the site of the primary tumour. Various angiogenic markers have been recognised, like Vascular Endothelial Growth Factor (VEGF), Angiopoietin-1 (Ang-1), Ang-2, Cluster of Differentiation (CD34), in head and neck neoplasms. The specificity and sensitivity of CD34 helps in vascular endothelial cell staining. CD34 is a type I transmembrane molecule of 110 kDa that is heavily glycosylated and expressed on haematopoietic progenitor cells selectively. The quantification of new blood vessels using CD34 antibody by Microvessel Density (MVD) can be used as a diagnostic and therapeutic indicator in many solid malignancies, like OSCC. Increased expression of positive CD34 antibody induces neoangiogenesis in neoplasms, upsurges the stemness of cancer and boosts its potential to metastasise. In this context, the present review focuses on use of CD34 antibody as a potential angiogenic marker that can be used to determine the aggressiveness and potential outcome of the tumour based on the literature overview.

Keywords: Cluster of differentiation, Head and neck carcinoma, Malignancy, Metastasis, Microvessel density, Neoangiogenesis

INTRODUCTION

Cancer is a multifactorial disease resulting from alteration in both the genotype and phenotype of predisposed persons [1]. Oral Squamous cell carcinoma is commonest neoplasm in head neck tumours. Its prevalence is observed in population at 5th decade of life. However, recently it has shown a marked incidence in adults ranging between 3rd and 4th decades of life [2-5]. The risk factors majorly include are tobacco, areca nut in different forms along with consumption of alcohol. In last couple of decades, in spite being advancement in treatment, diagnosis and study of the molecular mechanisms of OSCC, their still remains a high mortality rate and only a 5-year survival rate of the malignancy [6]. Among the six hallmarks of OSCC, as depicted in [Table/Fig-1], metastasis is the major risk factor that determines the prognostic outcome. Metastasis occurs through haematogenous spread, lymphogenous spread, or transcoelomic way. Neoangiogenesis is an essential process of many head and neck malignant tumours, as they are incapable of growing beyond 1-2 mm in size without it, thus facilitating invasion and metastasis [7]. Formation of new blood vessels is an essential mechanism physiologically that aids in healing of wounds, regeneration of organs and growth in postnatal life; however, it can pathologically causes progression in solid malignancy. Hence, neovascularisation forms a crucial step in altering the tumour microenvironment essential for survival of malignant cells. The vascular architecture in these newly formed blood vessels are highly disorganised, with huge gaps and termed as leaky vessels. The seeding of neoplastic cells occurs effortlessly and is implicated in the progression of OSCC and other head and neck tumours [8]. In malignancy the cancer cells follow an exponential growth pattern. The expression of various oncogenic proteins, along with diminished tumour suppressor genes, allows these cells to gain limitless potential to divide unprecedentedly, thereby forming the primary tumoural site. These neoplastic cells alter their phenotype subsequently and then break away from the



[Table/Fig-1]: Cycle of events occurring in the tumoural microenvironment of solid malignancies.
EMT: Epithelial-mesenchymal transition

site and enter the circulation via vascular or lymphatic pathways and establishes at new tissue organ [9].

Neovascularisation in OSCC is directly proportional to aggressiveness of the tumour, that in turn affects prognosis, metastasis and recurrence [10,11]. Newly formed blood vessels in the primary tumour have architectural abnormalities, increases the opportunity for neoplastic cells to invade the circulation. The blood vessels are abnormal, with incomplete or missing endothelial linings, interrupted or no basement membranes, lack of pericytes and physiological receptors [12,13]. Aberrant vascular architectures, such as contour irregularities, tortuosity, elongation of vessels, plenty of arteriovenous shunts and chaotic vascular networks, are seen in tumour neovascularisation. These alterations in the morphology of blood vessels affect functionality, like absence of vasomotion and shunt perfusion, obstruction of microvessels by leukocytes and tumour cells. This ensures in platelet aggregation, microthrombosis, haemoconcentration, interstitial backflow, extravasation of blood cells and haemorrhage [14,15]. Quantification of these vessels by hot

spot method, which denotes MVD, can be used as an appropriate method to correlate recurrence, metastasis and tumoural size in solid malignancies like OSCC [16].

Hypoxia is known to be very important trigger of angiogenesis and induces the synthesis of VEGF, which, in turn, induces synthesis of Angiopoietins. Angiopoietin-2 (Ang-2) causes detachment of pericytes from vascular wall and induces vessel destabilisation. Consecutively, VEGF stimulates Endothelial Cells (ECs) in destabilised vessels to form neovessels by promoting protein synthesis for Extracellular Matrix (ECM) degradation and by promoting EC migration and proliferation. ECs of neovessels produce Platelet-derived Growth Factor (PDGF), which attracts pericytes to neovessels. Maturation of neovessels occurs when pericytes attach to the ECs of neovessels, resulting in activation of transforming growth factor- β [17]. Hence, in the present era angiogenic markers with high specificity and sensitivity need to be identified that can be used in diagnosis to understand the potential outcomes of the disease course and recurrences in OSCC.

The CD34 is a 110 kDa transmembrane phosphoglycoprotein expressed on haematopoietic stem cells. Among the several transmembrane glycoproteins of CD34 family, the significant ones are CD34 haematopoietic antigen, endoglycan and podocalyxin. These proteins are utilised as biomarkers for stem, endothelial and haematopoietic precursor cells. They also play a crucial role in various cellular process like proliferation of progenitor cells, the maintenance of stemness of these subtypes of immature cells (which can be programmed to differentiate into any cell type), regulating cell adhesion and promoting the migration of haematopoietic cells. The role of CD34 is multifaceted. These groups of proteins also regulate the process of immune system by facilitating lymphocytic adhesion to high endothelial venules [18].

These cellular processes are indicated in both the physiological repair of various tissues and organ and also in the development and growth of variety of malignancies, like OSCC. Many studies have found that CD34 markers on Cancer Stem Cells (CSCs) are known to promote metastasis and recurrence in tumours [19]. Moreover, the expression of CD34 antibodies on CSCs can interfere with conventional cancer therapy. Therefore, the use of CD34 markers in CSC research and therapy warrants an in-depth research that will help to improve patient outcomes. Further investigations are a prerequisite to recognise their potential limitations and risks [18]. The present review elucidates the role of CD34 as a vascular progenitor marker in the prognosis of OSCC and its therapeutic applications based on currently available literature.

Various Markers for Angiogenesis and Microvessel Density (MVD)

The progression of tumours can be assessed by measuring the MVD in various head and neck carcinomas [20]. The most commonly used antibodies are VEGF, CD31, CD34 and CD105, that stain the endothelium of the blood vessels [21]. In a study assessed in 100 patients with Hepatocellular Carcinoma (HCC) using two parameters, namely CD34 and von Willebrand Factor (vWF), showed that CD34 is a superior endothelial marker than vWF and a high MVD-CD34 predicts early recurrence in HCC [22].

Mast Cell Density (MCD) is also associated with MVD. An increase in MVD results in an increase of MCD, suggesting that mast cells are attracted at the lesion site, which turns on an angiogenic switch in the course of tumourigenesis in OSCC [23]. In another study, immunohistochemical staining was done using three endothelial markers viz., vWF, CD31, CD34-in OSCC patients, showed that MVD is a prerequisite for assessing the disease outcomes. MVD-CD34 proved to be a useful marker that specifically stains the endothelial vasculature in malignancy [24].

The MVD, as measured by the hotspot method of Weidner, is a useful prognostic indicator in variety of solid malignancies. Thus, angiogenic

switch occurs initially in the development of OSCC and its rate of neovascularisation is directly proportional to tumour progression [25].

CD34 and its Role as a Prognostic and Diagnostic Marker in OSCC

The CD34 antigen, an angiogenic marker, is a heavily glycosylated type I transmembrane molecule that can be phosphorylated by diverged kinases, like Protein Kinase C and Tyrosine kinases. The use of appropriate antibody in clinical settings and research laboratory has been detected by distinct CD34 Monoclonal Antibodies (MAbs) through an array of its epitopes. In-depth analyses of the structure of CD34 have established that it is a sialomucin. The morphology of CD34 is characterised by the presence of carbohydrate moieties in its extended N-terminal region. This uniqueness helps in determining its reciprocation with diverged ligands [26].

A heterogeneous population of cell types expresses the CD34 antigen. The cell that show positive expression include subsets such as small vessel endothelial cells, tumours of epithelial origin, embryonic fibroblasts, bone marrow stromal progenitors, some cells in foetal and adult nervous tissue, areolar tissue, fat and somatic and visceral collagenous connective tissue [27-29]. Studies have shown that haematopoietic progenitors derived from foetal yolk sac, embryonic liver and extrahepatic embryonic tissues within 5-week embryo, several myxoid, fibrovascular and fibrohistiocytic mesenchymal tumours, fatty tumours derived from primitive fibroblast-like dendritic cells, also express CD34 [29-31].

The CD34 expression is also noticed in leukaemias, such as acute myeloid leukaemia (40%), pre-B acute lymphoblastic leukaemias (65%), acute T-lymphoid leukaemias (1.5%). Negative expression of CD34 is observed in chronic phase leukaemias and lymphomas [32,33].

Many studies have revealed a gradual increase in vascularity from normal mucosa to premalignancies cases like dysplasia and ultimately to Oral Squamous Cell Carcinoma (OSCC) [34-36]. The determination of neoangiogenesis in tumours, indicated by a vascular endothelial cell membrane marker, is a prerequisite for understanding tumour progression. CD34, which stains the membranes of endothelial cells, helps ascertain MVD in both metastatic and non metastatic OSCC [36].

The hotspot method introduced by Weidner N et al., to quantify MVD is mostly accepted, as it indicates the process of neovascularisation commonly found in the primary tumours [37]. In patients with OSCC, a high MVD was noted and CD34, being a vascular endothelial marker, can be used to assess MVD, reflecting tumoural angiogenesis [37,38]. In a study, MVD was compared between different stages of colorectal adenocarcinoma using CD34 and variations in the staining of the endothelial cell membrane, which showed high MVD observed in metastatic cases. The possible explanation for this variation is due to imbalance in the local or systemic stimulators and inhibitors of endothelial cell proliferation, resulting in disparity of neovascularisation in primary and metastatic tumours [39].

Thus, assessing MVD by using the hotspot areas of CD34 expression as a potential angiogenic marker can be applied to assess the aggressiveness and potential outcome of the tumours. The staining distribution of CD34 in the intratumoural region exhibited increased MVD in the peritumoral region than intratumoural region suggestive that the density of vessels was more in the advancing tumour front than the interior of the tumour itself [40]. Various studies support the phenomenon that angiogenesis is an important modulator for prognosis of OSCC. High MVD in primary OSCC increases the possibility for its metastasis, that affects the treatment modality in these patients [41-43].

The increased MVD in the tumoural tissue can also be attributed to hypoxia. Hypoxia causes a decrease in oxygen concentration, promotes angiogenesis, that in turn affects the aggressiveness and

progression of tumours. The most common factor that is increased in hypoxia is Hypoxia Inducible Factor (HIF), which stimulates neoangiogenesis. Solid tumours cannot grow more than 4 mm in the absence of oxygen; Hence, formation of these faulty new blood vessels promotes survival of the neoplastic cells and affects the process of metastasis [44].

Therapeutic Implications of CD34

Initially, CD34 protein was identified in haematopoietic stem cells and was used as a biomarker of haematopoietic stem cell progenitors. But, research in the last decade has shown its expression in various other cell types, such as fibrocytes, endothelial cells, interstitial cells and other non haematopoietic cells. This has expanded the research field for its potential therapeutic uses. The basic concept is to identify ways to guide CD34+ stem cells toward tissue renewal [18].

Tissue ischaemia mobilises endothelial precursor cells from bone marrow into bloodstream, through which them to reach the site of ischaemia and release cytokines to promote neovascularisation. This knowledge is utilised to transfer CD34+ haematopoietic progenitor cells for haematopoietic reconstitution. Intracoronary transfusion of autologous CD34+ endothelial cells has been studied for coronary neovascularisation in patients unfit for bypass surgery [19]. Similarly, it has been shown that transplantation of CD34+ cells into the hepatic artery in patients with severe liver disease improves circulation in liver of these patients. CD34+ Haematopoietic Stem Cells (HSC) transplantations have exhibited encouraging results in patient with diabetes mellitus as a measure of regeneration of pancreatic cell regeneration.

The CD34+ Cancer Stem Cells (CSCs) have been identified in leukaemia, breast cancer, lung cancer and other malignancies, where CD34+ CSCs have shown greater regenerating capacity and increased tumour infiltration capacity, when compared to CD34-negative cells. Hence, CD34+ can be used as a marker to predict tumour aggressiveness and resistance to chemotherapy in certain cancers. CD34+ proteins modulate the activity of integrins, which in turn interacts with selection to modulate signal transduction pathways mostly related to neovascularisation and thus tissue regeneration. This property of CD34+ has opened the floodgates of research for its therapeutic implications in solid tumours, like OSCC [28].

CONCLUSION(S)

Angiogenesis is an important mechanism in cancer cell growth and spread. It influences survival rates, as greater angiogenesis favours increased metastasis and lesser survival rate. The study of angiogenic markers using pan-endothelial markers and their quantification by the hotspot method provides us with MVD, which facilitates prognosis in patients suffering from OSCC. In comparison to pan-endothelial markers, CD34 serves as more specific marker to denote the MVD, that stains specifically stains the endothelial membranes of newly formed blood vessels. Hence, suggestive that increased CD34 positivity is a potential indicator of poor prognosis and recurrence of OSCC.

REFERENCES

- Capilla MV, Olid MNR, Gaya MVO, Botella CR, Ruiz VB. Factors related to survival from oral cancer in an Andalusian population sample. *Med Oral Pathol Oral Cir Bucal*. 2007;12(7):518-23.
- Shiboski CH, Schmidt BL, Jordan RC. Tongue and tonsil carcinoma: Increasing trends in the US population ages 20-44 years. *Cancer*. 2005;103(9):1843-49.
- Hirota SK, Migliari DA, Sugaya NN. Oral squamous cell carcinoma in a young patient- Case report and literature review. *An Bras Dermatol*. 2006;81:251-54.
- Sasaki T, Moles DR, Imai Y, Speight PM. Clinico-pathological features of squamous cell carcinoma of the oral cavity in patients <40 years of age. *J Oral Pathol Med*. 2005;34(3):129-33.
- Llewellyn CD, Johnson NW, Warnakulasuriya KAAS. Risk factors for oral cancer in newly diagnosed patients aged 45 years and younger: A case-control study in Southern England. *J Oral Pathol Med*. 2004;33(9):525-32.
- Neville BW, Tai DA. Oral cancer and precancerous lesions. *CA Cancer J Clin*. 2002;52(4):195-215.
- López-Graniel CM, Tamez de Leon D, Meneses-García A, Gómex-Ruiz C, Frias-Mendivil M, Granados-García M, et al. Tumor angiogenesis as a prognostic factor in oral cavity carcinomas. *J Exp Clin Cancer Res*. 2001;20(4):463-68.
- Ribatti D, Vacca A. Angiogenesis and anti-angiogenesis in haematological diseases. *Memo*. 2008;1:31-33.
- Fares J, Fares MY, Khachfe HH, Salhab HA, Fares Y. Molecular principles of metastasis: A hallmark of cancer revisited. *Sig Transduct Target Ther*. 2020;5:28.
- Seyfried TN, Huysentruyt LC. On the origin of cancer metastasis. *Crit Rev Oncol*. 2013;18:43-73.
- Lee WC, Kopetz S, Wistuba II, Zhang Z. Metastasis of cancer: When and how? *Annals of Oncology*. 2017;28(9):2045-47.
- Eelen G, Treps L, Li X, Carmeliet P. Basic and Therapeutic Aspects of Angiogenesis Updated. 2020;127:310-29.
- Guerra A, Belinha J, Mangir N, MacNeil S, Jorge RN. Sprouting angiogenesis: A numerical approach with experimental validation. *Ann Biomed Eng*. 2021;49(2):871-84.
- Wadhwan V, Sharma P, Saxena C, Venkatesh A. Grading angiogenesis in oral squamous cell carcinoma: A histomorphometric study. *Indian J Dent Res*. 2015;26(1):26-30.
- Ingaleswar PS, Pandit S, Desai D, Redder CP, Shetty AS, Mithun KM. Immunohistochemical analysis of angiogenesis by CD34 and mast cells by toluidine blue in different grades of oral squamous cell carcinoma. *J Oral Maxillofac Pathol*. 2016;20:467-73.
- Iratxe GZ, Oriol C. Unraveling the role of angiogenesis in cancer ecosystems. *Front Oncol*. 2018;8:248.
- Mahapatra N, Panda A, Dash K, Bhuyan L, Mishra P, Mohanty A. The study of expression of Hypoxia-Inducible Factor-1 Alpha (HIF-1 Alpha) and Hypoxia-Inducible Factor-2 Alpha (HIF-2 Alpha) in oral squamous cell carcinoma: An immunohistochemical study. *Cureus*. 2023;15(9):e45189.
- Radu P, Zuru M, Paic V, Bratucu M, Garofil D, Tigora A, et al. CD34-structure, functions and relationship with cancer stem cells. *Medicina (Kaunas)*. 2023;59(5):938.
- Kapoor S, Shenoy SP, Bose B. CD34 cells in somatic, regenerative and cancer stem cells: Developmental biology, cell therapy and omics big data perspective. *J Cell Biochem*. 2020;121:3058-69.
- Hueso M, Cruzado JM, Torras J, Navarro E. An exonic switch regulates differential accession of microRNAs to the Cd34 transcript in atherosclerosis progression. *Genes*. 2019;10(1):70.
- Tasev D, Konijnenberg LS, Amado-Azevedo J, van Wijhe MH, Koolwijk P, van Hinsbergh WW. CD34 expression modulates tube-forming capacity and barrier properties of peripheral blood-derived endothelial colony-forming cells (ECFCs). *Angiogenesis*. 2016;19(3):325-38.
- Poon RTP, Oi-lin Ng I, Lau C, Yu WC, Yan ZF. Tumor microvessel density as a predictor of recurrence after resection of hepatocellular carcinoma: A prospective study. *J Clin Oncol*. 2002;20(7):1775-85.
- Michailidou EZ, Markopoulos AK, Antoniadou DZ. Mast cells and angiogenesis in oral malignant and premalignant lesions. *Oral Dent J*. 2008;2:126-32.
- Li SH, Hun PH, Chou KC, Hsieh SH, Shieh YS. Tumor angiogenesis in oral squamous cell carcinomas: The significance of endothelial markers and hotspot selection. *Journal of Medicine and Science*. 2009;29(2):67-74.
- Florence ME, Massuda JY, Bröcker EB, Metzke K, Cintra ML, Souza EM. Angiogenesis in the progression of cutaneous squamous cell carcinoma: An immunohistochemical study of endothelial markers. *Clinics*. 2011;66(3):465-68.
- Siemerink MJ, Klaassen I, Vogels IMC, Griffioen AW, Van Noorden CJF, Schlingemann RO. CD34 marks angiogenic tip cells in human vascular endothelial cell cultures. *Angiogenesis*. 2012;15:151-63.
- Ferreras C, Cole CL, Urban K, Jayson GC, Avizienyte E. Segregation of late outgrowth endothelial cells into functional endothelial CD34- and progenitor-like CD34+ cell populations. *Angiogenesis*. 2015;18:47-68.
- Lee JH, Lee SH, Yoo SY, Asahara T, Kwon SM. CD34 hybrid cells promote endothelial colony-forming cell bioactivity and therapeutic potential for ischemic diseases. *Arterioscler Thromb Vasc Biol*. 2013;33:1622-34.
- Sasseti C, Van Zante A, Rosen SD. Identification of endoglycan, a member of the CD34/podocalyxin family of sialomucins. *J Biol Chem*. 2000;275:9001-10.
- Vieira SC, Silva BB, Pinto GA, Vassallo J, Moraes NG, Santana JO, et al. CD34 as a marker for evaluating angiogenesis in cervical cancer. *Pathol Res Pract*. 2005;201(4):313-18.
- Zavan B, De Francesco F, D'Andrea F, Ferroni L, Gardin C, Salzillo R, et al. Persistence of CD34 stem marker in human lipoma: Searching for cancer stem cells. *Int J Biol Sci*. 2015;11(10):1127-39.
- Salybekov AA, Kobayashi S, Asahara T. Characterization of endothelial progenitor cell: Past, present, and future. *Int J Mol Sci*. 2022;23(14):7697.
- Critser PJ, Yoder MC. Endothelial colony-forming cell role in neoangiogenesis and tissue repair. *Curr Opin Organ Transpl*. 2010;15:68-72.
- Macluskey M, Chandrachud LM, Pazouki S, Green M, Chisholm DM, Ogden GR, et al. Apoptosis, proliferation, and angiogenesis in oral tissues. Possible relevance to tumour progression. *J Pathol*. 2000;191(4):368-75.
- Carille J, Harada K, Baillie R, Macluskey M, Chisholm DM, Ogden GR, et al. Vascular endothelial growth factor (VEGF) expression in oral tissues: Possible relevance to angiogenesis, tumour progression and field cancerisation. *J Oral Pathol Med*. 2001;30(8):449-57.
- Iamaron A, Pongsirwet S, Jittidecharaks S, Pattanaporn K, Prapayasatok S, Wanachantararak S. Increase of mast cells and tumor angiogenesis in oral squamous cell carcinoma. *J Oral Pathol Med*. 2003;32(4):195-99.
- Weidner N, Semple JP, Welch WR, Foldman J. Tumor angiogenesis and metastasis--correlation in invasive breast carcinoma. *N Engl J Med*. 1991;324(1):01-08.

- [38] Miyahara M, Tanuma J, Sugihara K, Semba I. Tumor lymphangiogenesis correlates with lymph node metastasis and clinicopathologic parameters in oral squamous cell carcinoma. *Cancer*. 2007;110(6):1287-94.
- [39] Pandey S, Shukla S, Vagha S. Utility of CD34 in assessing microvessel density and its correlation with clinicopathological parameters in colorectal carcinoma patients. *Cureus*. 2023;15(11):e49186.
- [40] Ntellas P, Dadouli K, Perivoliotis K, Sogka E, Pentheroudakis G, Ioannou M, et al. Microvessel density and impact of angiogenesis on survival of resected pancreatic cancer patients: A systematic review and meta-analysis. *Pancreas*. 2019;48(2):233-41.
- [41] Svagzdys S, Lesauskaite V, Pavalkis D, Nedzelskiene I, Pranys D, Tamelis A. Microvessel density as new prognostic marker after radiotherapy in rectal cancer. *BMC Cancer*. 2009;9:95.
- [42] Shieh YS, Lee HS, Shiah SG, Chu YW, Wu CW, Chang LC. Role of angiogenic and non-angiogenic mechanisms in oral squamous cell carcinoma: Correlation with histologic differentiation and tumor progression. *J Oral Pathol Med*. 2004;33(10):601-06.
- [43] Des GG, Uzzan B, Nicolas P, Cucherat M, Morere JF, Benamouzig R, et al. Microvessel density and VEGF expression are prognostic factors in colorectal cancer. Meta-analysis of the literature. *Br J Cancer*. 2006;94:1823-32.
- [44] Muz B, de la Puente P, Azab F, Azab AK. The role of hypoxia in cancer progression, angiogenesis, metastasis, and resistance to therapy. *Hypoxia (Auckl)*. 2015;3:83-92.

PARTICULARS OF CONTRIBUTORS:

1. Reader, Department of Oral and Maxillofacial Pathology, Kalinga Institute of Dental Sciences, Bhubaneswar, Odisha, India.
2. Assistant Professor, Department of Oral and Maxillofacial Pathology, ESIC Dental College and Hospital, New Delhi, India.
3. Professor and Head, Department of Oral and Maxillofacial Pathology, GITAM Dental College, Vizag, Andhra Pradesh, India.
4. Reader, Department of Oral and Maxillofacial Pathology, Best Dental Science College and Hospital, Madurai, Tamil Nadu, India.
5. Lecturer, Department of Oral and Maxillofacial Pathology, CSI College of Dental Sciences and Research, Madurai, Tamil Nadu, India.

NAME, ADDRESS, E-MAIL ID OF THE CORRESPONDING AUTHOR:

Niva Mahapatra,
Campus 5, Kalinga Institute of Dental Sciences, Patia,
Bhubaneswar-751024, Odisha, India.
E-mail: niva.mahapatra@kids.ac.in

PLAGIARISM CHECKING METHODS: [\[Jain H et al.\]](#)

- Plagiarism X-checker: Jul 20, 2024
- Manual Googling: Nov 06, 2024
- iThenticate Software: Nov 08, 2024 (9%)

ETYMOLOGY: Author Origin

EMENDATIONS: 7

AUTHOR DECLARATION:

- Financial or Other Competing Interests: None
- Was Ethics Committee Approval obtained for this study? No
- Was informed consent obtained from the subjects involved in the study? No
- For any images presented appropriate consent has been obtained from the subjects. NA

Date of Submission: **Jul 19, 2024**Date of Peer Review: **Sep 12, 2024**Date of Acceptance: **Nov 11, 2024**Date of Publishing: **Dec 01, 2024**